

Examiners' Observations

Combining Accreditation with Treatment Protocols

Scott Finlay, DDS, FAGD, FAACD

Illustration by Dave Mazierski

Accreditation Case Type I presents the clinician with the broadest canvas to showcase his or her skills. This case type involves six or more indirect restorations within the maxillary arch, treating at least the incisors and canines. The key to delivering an optimal result lies in the clinician's ability to create a successful rapport with the laboratory technician. Smile design elements weigh heavily with this case type. While the restorations can be crowns, veneers, or a combination, it is critical that the practitioner demonstrate his or her ability to carefully address the patient's condition, esthetics, and overall health. The comprehensive understanding of materials, preparation designs, and adhesive techniques should facilitate conservation of tooth structure while still meeting the parameters of function and health.

The examiners evaluate cases based on a point system that identifies minor, major, and catastrophic faults. A passing score is -7 or better. The examiners are also given the latitude to reward the candidate with a +1 point, in situations where the result deserves additional merit. Dr. Shimizu's case passed unanimously with scores that ranged from -5 to -7. Almost all of the criteria faults were identified as minor and two examiners rewarded Dr. Shimizu with a +1. No case is perfect; the goals of Accreditation are to create a vision and demonstration of excellence, not perfection.

The comprehensive understanding of materials, preparation designs, and adhesive techniques should facilitate conservation of tooth structure while still meeting the parameters of function and health.

Dr. Shimizu achieved a wonderful result for his patient. The preoperative indications for treatment supported the final treatment plan. Dr. Shimizu extended treatment to include eight teeth because of the clinical indications. The indications for treatment are driven by the functional and health needs of the patient. Dr. Shimizu followed an established treatment protocol that helped to ensure a predictable result.

The examiners identified several common deficiencies in this case; often, these criteria are inter-related:

- One of the initial observations was the excessive length of connectors and the effect this had on the periodontal health and architectural harmony (*Criteria #64, #71, and #72*). An accepted guideline that is observed in nature relates to the proportion and size of the apparent contact zone or connectors between adjacent teeth. Typically, the ideal connector zone between the central incisors is 50% of the length of the centrals.¹ The size of these connectors decreases in a symmetrical fashion as you move posterior (**Fig 1**). The effect of excessive connector length in this case appears to contribute to the impingement upon the cervical embrasures and the blunting of the papilla. The

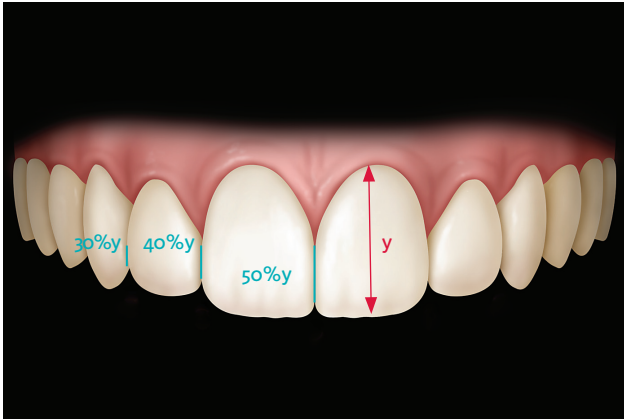


Figure 1: The apparent contact zone between the centrals is ideally 50% of the visual length of the centrals. Connectors between the centrals and laterals are 40% of this length, and the connectors between the laterals and cupids are 30% of this length (50/40/30 rule).

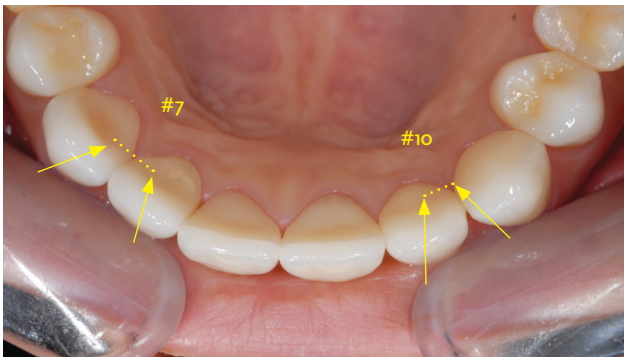


Figure 2: The management of the facial line angles can have a significant impact on the visual reveal of the tooth.

examiners noted the asymmetry of gingival zeniths, papilla heights, and inflammation of the tissue.

- *Criteria #87* focuses on the visual harmony of contralateral teeth. The examiners identified a lack of symmetry of the visual width of the lateral incisors. This requires the careful management of the facial line angles and can be readily identified from the occlusal view (**Fig 2**).² Although the occlusal view is not how teeth are typically viewed in a social setting, it is a valuable perspective in helping to appreciate the impact that these line angles have on the reflective surfaces of the teeth. In this case, the occlusal view is helpful in visualizing why the facial plane of #10 appears narrower compared to #7. The cuspids also lack similar balance in contour and shape.
- *Criteria #56* identifies the effectiveness in utilizing translucency to mimic nature and to harmonize with the balance of the smile.³ Several of the examiners found the intensity, volume, and pattern of the translucency to be slightly excessive and not reflective of what would otherwise be observed in nature.

Accreditation presents a consistent measurement of excellence in providing esthetic functional restorations of our patients' smiles. Dr. Shimizu has demonstrated his ability to meet this standard. He should be very proud of the result he achieved for his patient.

References

1. Morley J. A multidisciplinary approach to complex aesthetics restoration with diagnostic planning. *Pract Perio Aesth Dent.* 2000;12:575-7.
2. Snow SR. Esthetic smile analysis of maxillary anterior tooth width: the golden percentage. *J Esthet Dent.* 1999;11(4):177-84.
3. Villarroel M, Fahl N Jr., De Sousa AM, De Oliveira OB. Direct esthetic restorations based on translucency and opacity of composite resins. *J Esthet Restor Dent.* 2011 Apr;23(2):73-87. **jCD**



Dr. Finlay is an AACD Accredited Fellow and has been an AACD Accreditation Examiner since 2008. A 1986 graduate of the University of Maryland, Baltimore College of Dental Surgery, Dr. Finlay practices in Arnold, Maryland.
Disclosure: The author did not report any disclosures.